CHAPTER 91 Intestinal and multivisceral transplantation

Learning objectives

To understand:

- The indications for intestinal transplantation
- The assessment process for intestinal transplantation
- The different transplant types
- Both the medical and surgical complications associated with intestinal transplantation
- The outcomes associated with intestinal transplantation

BACKGROUND

Intestinal and multivisceral transplantation can be a life-saving therapy for patients with complications from the treatment of intestinal failure. Indications for this highly specialised type of transplant are broadening to include acute vascular catastrophes and some otherwise irresectable intra-abdominal tumours (e.g. desmoids and pseudomyxoma peritonei). Since the first successful multivisceral transplant in the late 1980s, more than 4000 transplants have taken place worldwide and outcomes continue to improve. Intestinal transplantation is the most challenging area of abdominal transplantation, with higher rates of complications than other transplant groups. These complications include rejection, sepsis, post-transplant lymphoproliferative disease (PTLD) and graft-versus-host disease (GVHD).

Graft and patient outcomes for isolated intestinal transplants are close to those for long-term parenteral nutrition (PN). The role of intestinal transplantation may be changing with earlier referral to try to avoid the complications of long-term PN, including intestinal failure-associated liver disease (IFALD).

INTRODUCTION

The first reported intestine-containing transplant in humans was performed in 1966, when a short segment of duodenum was included in a pancreas transplant. This was followed by attempts to transplant more substantial amounts of intestine, but these did not result in long-term survival. It was not until 1988 that the first 'successful' intestine-containing transplant was reported.

At this time intestinal transplants were a rarity but with increasing experience (both surgical and immunological) outcomes have improved, making intestinal transplantation a relatively routine procedure.

Changes in immunosuppression regimes (depleting antibodies and tacrolimus) have improved rates of rejection, a complication that is difficult to control and can be life-threatening.

In 1996 the International Intestinal Transplant Registry was established and reported a total of 180 transplants performed in 25 centres worldwide. By 2019 this number was over 4100, with almost double the number of active centres. The majority of transplants have been performed in the USA and Europe, with the most prolific units performing over 10 adult transplants per year.

With improvements in the management of paediatric intestinal failure the number of multivisceral and intestinal transplants in this group has fallen.

INDICATIONS FOR TRANSPLANTATION

Complications from PN for irreversible intestinal failure are the most well-established indications for intestinal transplantation (*Table 91.1*). Short bowel syndrome (SBS) is the most frequent cause for the need for PN. The aetiologies of SBS vary between the adult and paediatric population.

The most common causes for SBS in the paediatric population are volvulus, gastroschisis, necrotising enterocolitis and intestinal dysmotility or pseudo-obstruction. The last two result in functional SBS.

The most common causes for SBS in adults result from bowel resections owing to mesenteric ischaemia, inflammatory bowel disease (most commonly Crohn's disease), benign tumour resection and dysmotility or pseudo-obstruction.

Until recently, intestinal transplantation was only considered for patients with complications of PN, including loss of vascular access, recurrent life-threatening line infections (especially fungal infections) and IFALD. Increasingly patients are being transplanted for quality-of-life indications, although this remains controversial.

Burrill Bernard Crohn, 1884–1983, gastroenterologist, Mount Sinai Hospital, New York, NY, USA, described regional ileitis in 1932.

TABLE 91.1 Current indications for intestinal transplantation in the UK.

1. Life-threatening complications of parenteral nutrition a. Progressive IFALD or non-IFALD • Assessed by biochemistry and biopsy • Combined intestinal and liver transplant is best considered in the presence of advanced liver disease (portal hypertension or advanced fibrosis)
b. Severe sepsis • More than one life-threatening episode of catheter-related sepsis for which no remediable cause can be identified • Endocarditis or other metastatic infection
c. Limited central venous access • Venous access limited to three major conventional sites in adults (above and below the diaphragm) and two major conventional sites above the diaphragm in children • Conventional central venous sites are defined as internal jugular, subclavian and femoral veins
2. Very poor quality of life thought likely to be correctable by transplantation
3. Surgery to remove a large proportion of the abdominal viscera considered untenable without associated multivisceral transplantation (e.g. extensive desmoid disease, extensive critical mesenteric arterial disease)
4. Localised malignancy considered amenable to curative resection requiring extensive evisceration (e.g. localised neuroendocrine tumours). Particular caution should be exercised in this group and patients should be discussed in a multidisciplinary multicentre forum (e.g. National Adult Small Intestinal Transplant [NASIT] forum)
5. Where the transplantation procedure is expected to preclude the possibility of future intestinal transplantation (e.g. loss of venous access or further human leukocyte antigen sensitisation)
6. Where the need for subsequent intestinal transplantation is considered likely and the risk of death is increased by excluding the intestine from the graft *Examples include predictable problems related to administering immunosuppression (e.g. line sepsis), or continuing severe intestinal disease such as diabetic visceral neuropathy, or ultra-short bowel syndrome, which may cause fluid, electrolyte and acid–base balance problems that would damage an existing or planned renal graft*
7. Transplantation of additional organs for feasibility reasons a. Renal transplantation b. Adults and children with corrected GFR of <45 mL/min/m^2 are evaluated for the possibility of simultaneous renal transplantation

GFR, glomerular filtration rate; IFALD, intestinal failure-associated liver disease.
Adapted from NHS Blood and Transplant (https://www.odt.nhs.uk/transplantation/small-bowel/).

If the indication for transplant is IFALD, the degree of liver impairment influences the organs required at transplant. Mild to moderate liver fibrosis may allow an isolated intestinal transplant to be undertaken. This results in improved patient outcomes, better organ utilisation and reversal of liver fibrosis with discontinuation of PN. Severe liver fibrosis or cirrhosis will necessitate a liver-containing graft.

Indications for intestinal transplantation continue to change and now include to facilitate the resection of some tumours (desmoids and pseudomyxoma peritonei). In this situation, without intestinal transplantation, extensive evisceration would render the patient dependent on PN. Hepatic cirrhosis with extensive portomesenteric thrombosis may make isolated liver transplantation technically impossible, so multivisceral transplantation may be considered for some individuals.

Acute widespread splanchnic ischaemia (arterial and venous) is a rare but growing indication for super-urgent intestinal and multivisceral transplantation as well as other acute abdominal catastrophes.

ASSESSMENT FOR TRANSPLANTATION

Assessment for a multivisceral/intestinal transplant requires a multidisciplinary approach, including:

- transplant surgeons;
- intestinal failure physicians;
- transplant anaesthetists;
- hepatologists;
- psychiatrists and/or psychologists;
- radiologists;
- infectious disease physicians;
- transplant specialist nurses;
- dieticians.

Assessment of venous access and the degree of liver fibrosis is critical. Patients on PN for a substantial time or who have ultra-short gut are at high risk of developing IFALD. They will need a liver biopsy as part of the assessment process. Detailed venous mapping is essential in all candidates.

Appropriate assessment of the cardiovascular and respiratory systems is necessary. Upper and lower gastrointestinal endoscopies may be necessary.

Cross-sectional imaging of the abdomen to assess the abdominal anatomy is central to operative planning.

Significant renal impairment may result in the need to consider inclusion of a kidney at the time of transplant.

Patients should have anaesthetic and psychiatric assessment and dietetic review.

TYPES OF TRANSPLANT

Multivisceral or intestinal transplant covers a number of different 'cluster' transplants, as shown in *Table 91.2* and *Figure 91.1*.

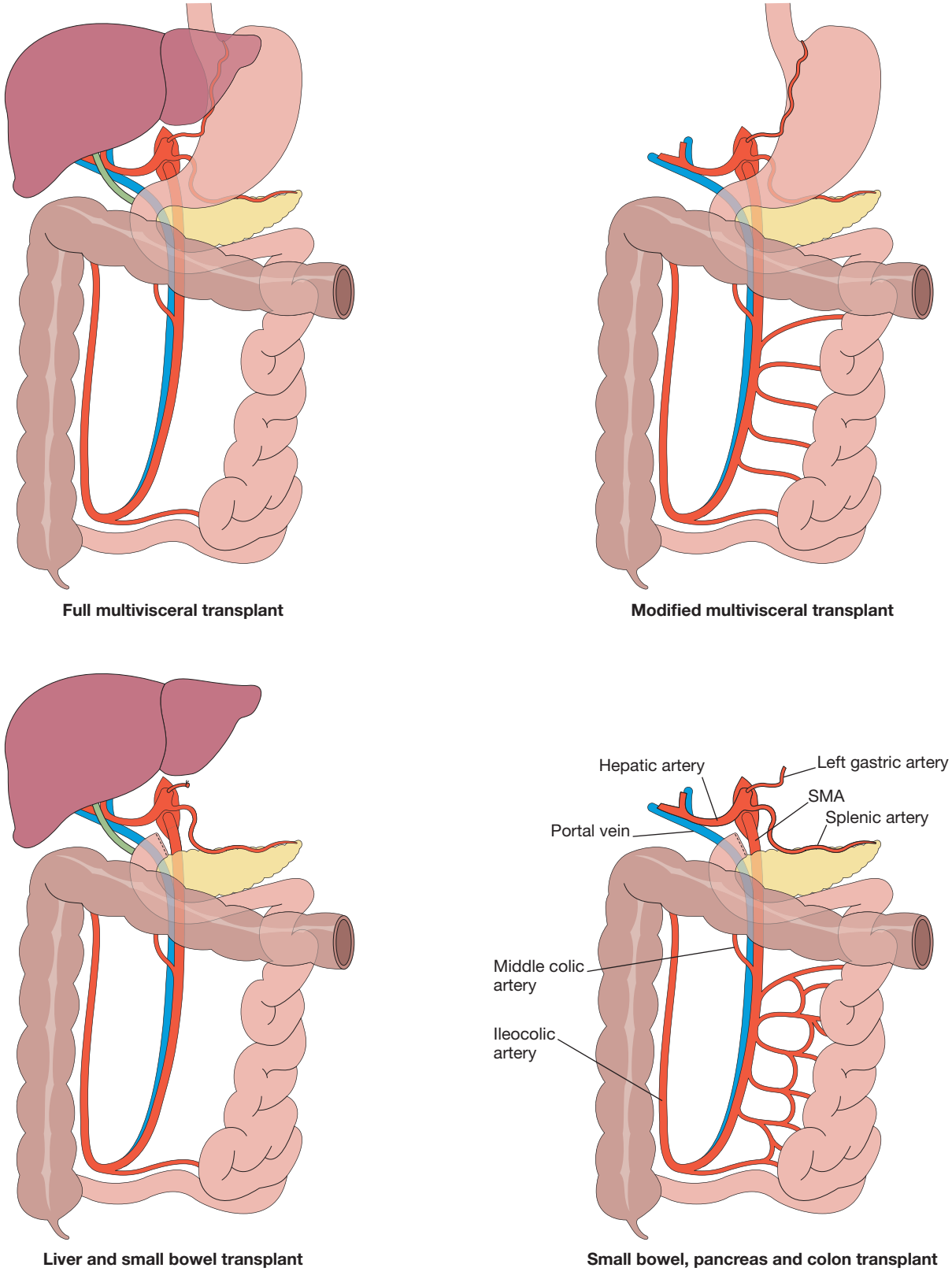

Figure 91.1 Types of intestinal transplant. SMA, superior mesenteric artery.

TABLE 91.2 'Cluster' transplants.

Transplant	Organs included	Extent of resection	Proximal enteric anastomosis
Small intestinal and colon transplant	Small intestine and colon (with/without pancreas)	Small intestine and part of colon	Duodenum or proximal jejunum
Modified multivisceral transplant	Stomach, pancreas, small intestine and colon	Stomach, pancreas, spleen, small intestine and part of colon	Proximal stomach or oesophagus
Liver and small bowel transplant	Liver, pancreas, small intestine and colon	Liver, small intestine and part of colon	Duodenum or proximal jejunum
Multivisceral transplant	Liver, stomach, pancreas, small intestine and colon	Liver, stomach, pancreas, spleen, small intestine and part of colon	Proximal stomach or oesophagus

PREOPERATIVE PLANNING

The decision regarding the type of transplant to be performed is dependent on a variety of patient factors. Intraoperative flexibility is necessary and may change the type of transplant undertaken.

A robust plan for adequate venous access is necessary and may require pretransplant venous reconstruction by the interventional radiology team or surgical reconstruction.

If substantial intraoperative blood loss is predicted, selective arterial embolisation may be considered. Commonly this will involve the superior mesenteric artery and coeliac axis, but more selective embolisation can be undertaken if preservation of the stomach or the pancreaticoduodenal complex is planned.

THE TRANSPLANT

Multivisceral/intestinal transplants are almost invariably performed with organs donated from deceased brain dead donors. A small number of living donor intestinal transplants have been performed.

In intestinal and multivisceral transplant procedures the donor and recipient operations occur simultaneously; this is not the case for liver and kidney transplantation. This is to minimise cold ischaemia time (the intestine is intolerant of ischaemia and ideally cold ischaemia times of less than 6 hours are required).

The recipient operation is often complex and technically challenging. Portal hypertension, extensive adhesions and distorted anatomy all result in these patients having surgically hostile abdomens, making the explant challenging. Substantial blood loss and transfusion may result in severe coagulopathy. Preoperative embolisation can reduce blood loss significantly. The extent of the explant is dependent on what transplant is required, a full multivisceral being the most extreme (*Figure 91.2*).

At retrieval the organs are retrieved en bloc (*Figure 91.3*), with the vascular inflow coming from the coeliac axis and superior mesenteric artery (SMA) and the venous outflow from either the portal vein (in a non-liver-containing graft) or the vena cava when a liver is implanted. This technique was first described by Starzl in the 1990s.

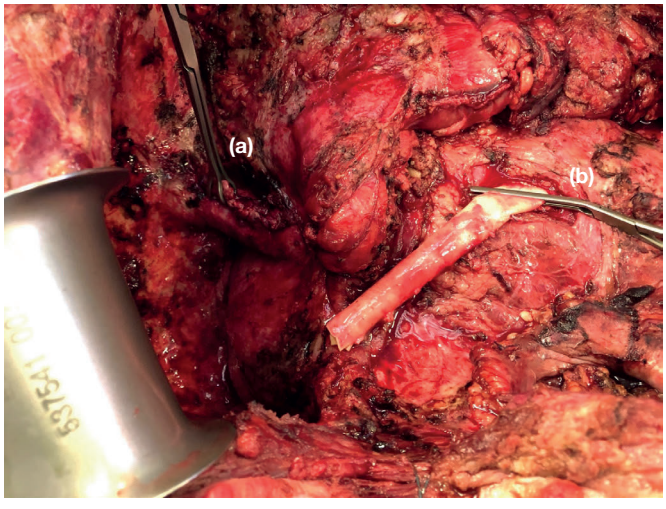

Figure 91.2 Intraoperative picture following exenteration. (a) Clamp on the retrohepatic cava in preparation for caval anastomosis (venous outflow for the multivisceral graft). (b) Clamp on the donor thoracic aorta anastomosed to the infrarenal aorta of the recipient (arterial inflow to the multivisceral graft).

Figure 91.3 Intraoperative picture following exenteration. Multivisceral graft (stomach, small bowel, pancreas and liver) immediately prior to implantation. The graft is preserved using University of Wisconsin solution.

Thomas Earl Starzl, 1926–2017, Distinguished Professor of Surgery, University of Pittsburgh School of Medicine, Pittsburgh, PA, USA. Referred to as 'the father of modern transplantation'. He was awarded the USA's highest honour for scientific achievement, the Medal of Science, in 2005.

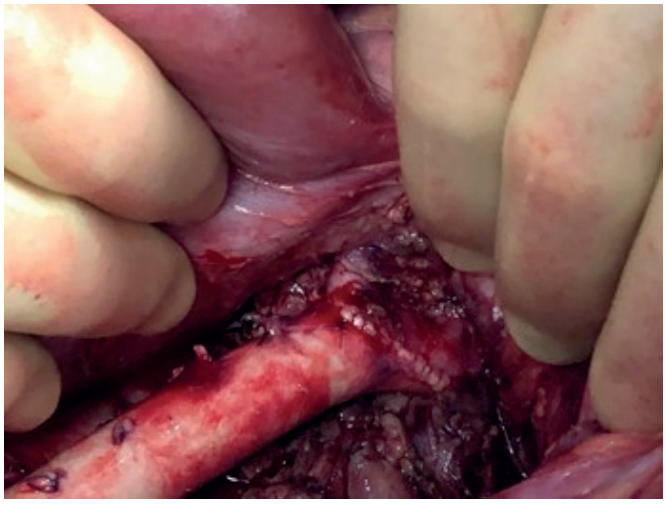

Figure 91.4 Intraoperative picture following exenteration. A Carrel patch (donor superior mesenteric artery and coeliac artery) onto an aortic conduit constituting the arterial inflow to the multivisceral block.

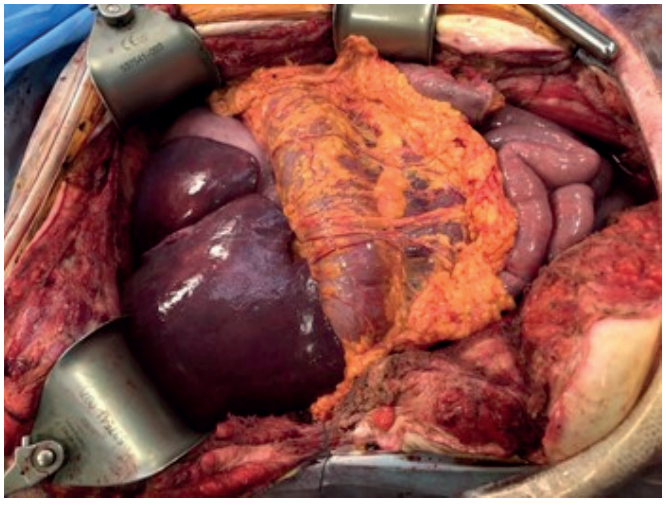

Figure 91.5 Intraoperative picture following exenteration. Intraoperative photograph of a multivisceral block (stomach, liver, small bowel, pancreas and colon) following reperfusion.

Arterial inflow to the graft is usually achieved from the infrarenal aorta. Commonly a section of donor thoracic aorta is used as an arterial conduit, onto which the donor aortic patch containing SMA and coeliac artery is anastomosed (*Figure 91.4*). In intestine-only grafts (not including the pancreas) the inflow is the SMA, which is either anastomosed directly to the aorta (as a Carrel patch) or the recipient SMA or a conduit can be fashioned from donor iliac vessels.

When undertaking a liver-containing graft, venous outflow from the whole graft is via the hepatic veins and inferior vena cava (IVC). For non-liver-containing grafts the venous outflow is via the portal vein. This can be drained either systematically via the IVC or into the portal circulation.

Following reperfusion of the graft (*Figure 91.5*) the enteric anastomoses are performed. This requires a proximal enteric anastomosis and a distal stoma or anastomosis. In some circumstances (modified multivisceral transplant) a biliary anastomosis may be required.

The proximal bowel anastomosis may be either oesophagogastric, oesophagojejunal, gastrogastric, gastrojejunal or jejunojejunal. If an oesophagogastric or gastrogastric anastomosis is performed, then a pyloroplasty is necessary (the block lacking vagal innervation).

An end stoma is the simplest option distally, but, where safe, a primary distal anastomosis can be considered. In most circumstances a covering ileostomy is performed. This allows ready access to the graft for endoscopic surveillance.

ABDOMINAL CLOSURE

One of the most challenging parts of a multivisceral/intestinal transplant is achieving abdominal closure. Multiple previous laparotomies and enterocutaneous fistulae can result in a rigid abdominal wall and loss of the abdominal domain owing to extensive bowel resections. Many techniques to achieve primary closure under these circumstances have been developed. These include preoperative tissue expansion, the use of biological meshes and plastic surgery techniques (e.g. vascularised pedicle flaps).

Transplantation allows novel techniques to be used, including transplantation of part or all of the abdominal wall from a donor. The rectus sheath from the donor can be used as a non-vascularised sheet of fascia. Prior to implantation the muscle and fat are removed from the rectus abdominis graft, leaving the fascial and peritoneal components. This can then be used as a biological 'mesh'. Unlike other biological mesh it vascularises rapidly. Skin coverage is achieved by mobilisation of the recipient's skin and subcutaneous tissues, although rarely a skin graft is needed.

Vascularised abdominal wall grafts can also be used where the anterior abdominal wall with its over lying subcutaneous fat and skin is transplanted using the inferior epigastric arteries and veins as the vascular inflow and outflow.

POST-TRANSPLANT COMPLICATIONS

With the complexity of multivisceral/intestinal transplantation complications are common (*Table 91.3*).

Early postoperative

Many patients considered for multivisceral/intestinal transplantation have underlying prothrombotic tendencies. A defined prothrombotic disease may be characterised but a history of multiple previous thrombotic episodes without a specific diagnosis necessitates a need for anticoagulation after transplantation. Balancing the risks of bleeding and thrombosis after transplant is challenging.

Enteric anastomotic leaks can occur after transplantation, most commonly if an oesophagogastric anastomosis is

Alexis Carrel, 1873–1944, French surgeon, received the Nobel Prize in Physiology or Medicine in 1912 for developing a method of suturing blood vessels.

TABLE 91.3 Early and late complications in multivisceral/intestinal transplantation.

	Surgical	Medical
Early	• Vascular (thrombosis, bleeding, secondary haemorrhage, mycotic aneurysm) • Enteric leak (anastomotic or non-anastomotic) • Abdominal collections (chylous, pancreatic, infected) • Pancreatitis (graft or native) • Stomal complications	• Renal impairment • Drug related (PRES, TMA, pancreatitis) • Infections (viral, bacterial, fungal) • GVHD • PTLD • Acute cellular rejection
Late	• Thrombosis • Mycotic aneurysm • Hernias • Stomal complications	• Renal impairment • Acute cellular rejection • Chronic rejection • PTLD • Immunosuppression-related malignancy

GVHD, graft-versus-host disease; PRES, posterior reversible encephalopathy syndrome; PTLD, post-transplant lymphoproliferative disease; TMA, thrombotic microangiopathy.

undertaken. Given that the enteric anastomoses are performed on previously ischaemic bowel, often under circumstances where inotrope requirements are substantial, the rate of anastomotic leaks is surprisingly low.

When an enteric leak does occur, the immunosuppressed state of the patient can result in an atypical presentation. Therefore, a high index of suspicion is needed should a patient fail to progress as expected postoperatively.

Proximal enteric anastomotic leaks, especially involving the oesophagus, are the most challenging to deal with. Oesophagogastric anastomotic leaks have a significant morbidity and mortality in the general population and are even more challenging to manage in an immunosuppressed patient. The use of an EndoVac® has improved management of these patients. A vacuum (vac) sponge fixed to a nasogastric tube is placed endoscopically in the cavity at the site of the leak. This controls the leak and facilitates healing without operative intervention.

Intra-abdominal collections are common and should be treated by aggressive radiological drainage where possible. These collections may be chylous and may require nutritional modifications, either PN or (if the patient is enterally fed) a medium-chain triglyceride diet should be adopted.

Immunosuppression and rejection

The rate of acute cellular rejection for intestinal grafts is higher than for any other abdominal organ. This is reflected in the magnitude of immunosuppression required. As with other solid organ transplants acute cellular rejection is most common in the first few months after transplantation, although it can occur at any time.

Multivisceral/intestinal transplant immunosuppression regimens commonly utilise an induction agent, usually a lymphocyte-depleting antibody such as antithymocyte globulin (ATG) or alemtuzumab. Paediatric regimens commonly use non-depleting antibody induction. Maintenance immunosuppression comprises a calcineurin inhibitor (most commonly tacrolimus), an antimetabolite (mycophenolate or azathioprine) and prednisolone. In addition, some programmes supplement this with early addition of an mTOR (mammalian target of rapamycin) inhibitor (sirolimus or everolimus).

Acute cellular rejection is usually initially manifested in the terminal ileum. Rarely other organs (liver/pancreas) may be affected without intestinal rejection.

Rejection most commonly presents with increased stoma output or diarrhoea, sometimes with an associated fever. Severe (exfoliative) acute cellular rejection with loss of intestinal mucosa results in rapid bacterial translocation and sepsis. In any intestinal transplant recipient presenting with sepsis or septic shock, a diagnosis of rejection needs to be considered.

Endoscopic assessment and biopsy of the graft are required for the diagnosis and assessment of the severity of acute cellular rejection. Graft surveillance in a protocolised manner is performed in some programmes; others respond to symptoms suggestive of rejection (i.e. an increase in stoma output).

At endoscopy, rejection can range from mild, with some erythema of the mucosa, to moderate, with some ulceration, to severe, with confluent loss of mucosa. At biopsy, salient features of rejection are an inflammatory infiltrate in the lamina propria, crypt loss and ulceration and an increase in apoptotic bodies in the base of the crypts.

Rejection is treated primarily with high-dose intravenous pulsed steroids. If the rejection is steroid resistant then further lymphocyte depletion may be needed with either ATG or alemtuzumab.

Infectious complications

Infection is the leading cause of death in multivisceral/intestinal transplant recipients. This is as a consequence of the degree of immunosuppression and also the potential for bacterial translocation across the graft mucosa. Opportunistic infections, common to all solid organ transplant recipients, such as cytomegalovirus (CMV), *Pneumocystis jirovecii* (PJP), adenovirus, Epstein–Barr virus (EBV) and fungal infections, are all more common following intestinal transplantation. Appropriate prophylaxis with antiviral (valganciclovir or aciclovir), antifungal (fluconazole) and anti-PJP (co-trimoxazole) agents is critical.

Infective enteritis is common among transplant recipients and can mimic rejection, thus it is important to send stool for culture and viral polymerase chain reaction when a patient presents with a high-output stoma or diarrhoea. Rejection triggered by infection is possible and a high index of suspicion and early repeat endoscopy are important if clinical improvement does not occur.

Michael Anthony Epstein, b. 1921, Professor of Pathology, University of Bristol, Bristol, UK.
Yvonne Barr, 1931–2016, virologist who emigrated to Australia. Epstein and Barr discovered this virus in 1964.

Long-term complications

PTLD is a potential complication of immunosuppression for any patient after transplant. The incidence in intestinal transplant recipients is higher than for other solid organ transplant recipients – up to 17% in some series. This is likely to be due to both the level of immunosuppression and the amount of lymphoid tissue associated with an intestinal-containing graft. PTLD should be considered if there is a persistent positive EBV viraemia or B symptoms such as night sweats, unexplained fevers and weight loss. If diagnosed with PTLD the first-line treatment is usually with rituximab and immunosuppression reduction. This has to be done with great caution in multivisceral/intestinal transplant recipients because of the risk of rejection and the consequences thereof.

The extent of lymphoid tissue associated with the multivisceral/intestinal graft increases the risk of GVHD. Outcomes from GVHD in this patient group can be very poor. The most common presenting symptoms of GVHD are a rash, fever and bone marrow suppression. Optimal management of GVHD is unclear and proposed strategies include both enhancement and also reduction of immunosuppression. Management is guided by the level of peripheral T-cell chimerism. There is an increasing trend towards withdrawing immunosuppression initially to rebalance the equilibrium between the host and donor immune systems. Bone marrow involvement and ultimately failure is almost universally fatal.

Deterioration in renal function is common to all solid organ transplant groups but is most marked following multivisceral/intestinal transplantation. The cause of this is multifactorial but is likely to include contributions from the physiological insult of surgery, the use of nephrotoxic medication (e.g. tacrolimus) and fluid losses associated with the stoma. It is imperative to maintain good hydration postoperatively and home intravenous fluids may be needed initially post discharge. Immunosuppression modifications including conversion from calcineurin inhibitor-based protocols to mTOR inhibitors may prevent further deterioration of renal function. These interventions need to be undertaken with caution as they may precipitate an episode of acute cellular rejection.

OUTCOMES

Graft and patient outcomes vary depending on the type of transplant undertaken with survival post-multivisceral transplant being markedly poorer than isolated small intestinal transplant. As with many transplant groups, outcomes are improving over time and the outcomes in the last published Intestinal Transplant Registry report in 2015 showed continued improvement in both 1- and 5-year patient survival. In 2019 the overall 1-year patient survival for intestinal-only grafts was >80% and for liver-containing grafts was >70%. A decade ago the 1-year patient survival for *all* intestinal transplant recipients (intestine only and multivisceral grafts) was 70%. Five-year survival rates have also improved and the long-term results of intestinal-only transplants are now comparable to those of long-term PN. Intestinal transplantation may have progressed to the stage at which it may be offered to patients on PN to improve their quality of life rather than just for those with life-threatening complications of PN.

SUMMARY

Multivisceral and intestinal transplantation remains a complex and uncommon treatment, however it can be life-saving. The risks are high but with improvements in surgical techniques, especially the introduction of preoperative embolisation, the intraoperative risks have improved. With this and a better understanding of how to manage the varied and complex postoperative complications, outcomes continue to improve.

Intestinal transplantation for patients on PN was previously reserved for those with life-threatening complications of this treatment. Outcomes have improved such that, in certain circumstances, it can now be offered to improve quality of life.

With time, improvement in patient management may allow intestinal transplantation to fulfil the same role for patients on PN as kidney transplantation currently offers those on dialysis: to improve both quality and length of life.

The need for liver-containing grafts will always remain for those who require a liver transplant but are unable to have a single-organ transplant for anatomical reasons. With improvements in liver functional assessment and increasing awareness of the possibility of earlier intestinal transplantation, it may be possible to reduce and hopefully eliminate the need for liver transplantation for IFALD. The benefits for the individual in terms of improved survival and also the population with better organ utilisation are substantial.

The main cause of death in multivisceral and intestinal transplant recipients remains sepsis. This is frequently associated with a preceding episode of severe acute cellular rejection and so further developments in immunosuppression regimens will be necessary to continue to improve patient outcomes.

FURTHER READING

Abu-Elmagd K, Mazariegos G, Armanyous S *et al.* Five hundred patients with gut malrotation: thirty years of experience with the introduction of a new surgical procedure. *Ann Surg* 2021; **274**(4): 581–96.

Matsumoto CS, Subramanian S, Fishbein TM. Adult intestinal transplantation. *Gastroenterol Clin North Am* 2018; **47**(2): 341–54.

Tzakis AG, Kato T, Levi DM *et al.* 100 multivisceral transplants at a single center. *Ann Surg* 2005; **242**(4): 480–90; discussion 491–3.